

Fine-needle aspiration accuracy in the diagnosis of primary epithelioid angiosarcoma of the adrenal gland: a case report and review of the literature

Tullio Torelli¹, Stefano Radaelli², Maurizio Colechia³, Biagio Paolini³, Mario Achille Catanzaro¹, Nicola Nicolai¹, Davide Biasoni¹, Luigi Piva¹, Silvia Stagni¹, Roberto Salvioni¹

Abstract

Primary epithelioid angiosarcoma of the adrenal gland is extremely rare. Only 37 cases have been reported in the scientific literature.

Here we describe the case of a 55-year-old woman affected by metastatic angiosarcoma in the right adrenal gland, who died few days after the histological diagnosis made by fine-needle aspiration (FNA). This is the second case of primary epithelioid angiosarcoma diagnosed by FNA among scientific articles published in English in PubMed. Microscopically, the tumor showed a predominant epithelioid differentiation, thus making the diagnostic process more difficult than usual. Immunohistochemical examination revealed positive reactivity for cytokeratin, CD31, and CD34. The literature shows that epithelioid adrenal angiosarcoma has poor clinical outcome, especially when metastatic at presentation.

Keywords: Adrenal glands; Hemangiosarcoma; Biopsy, Fine-Needle; Primary Epithelioid Angiosarcoma; Fine-Needle Aspiration

Accuratezza diagnostica dell'agobiopsia nell'angiosarcoma epitelioido primario della ghiandola surrenale: caso clinico e review della letteratura

CMI 2017; 11(1): 7-16

<http://dx.doi.org/10.7175/cmi.v11i1.1256>

INTRODUCTION

Angiosarcomas are malignant tumors arising from the endothelial lining of blood vessels and accounting for less than 1% of all soft tissue sarcomas, which represent 1% of all solid tumors in adults. That means that the incidence of angiosarcoma is 0.1-0.2/100,000 per year. Adrenal gland is an uncommon site for angiosarcoma. Usually, it occurs in skin, soft tissue, breast, bone, liver, and spleen and has poor long-term prognosis [1]. No predisposing factors for primary adrenal angiosarcoma have been identified yet.

CASE REPORT

A 55-year-old woman was admitted to our Urology Unit on January 2014 to undergo a

biopsy of right adrenal mass. Clinically, the patient suffered from continuous pain in the right lumbar region, a significant weight loss in the past two months (about 15 kg), and severe asthenia. Before hospitalization,

Why we describe this case

Epithelioid angiosarcoma of the adrenal gland is a very rare and aggressive tumor, with no specific clinical or radiological patterns. Diagnosis requires detailed pathologic examination accompanied by immunohistochemical studies using endothelial markers. When FNA is used for diagnosis, this process becomes much challenging due to the minimal amount of tissue available for examination

- ¹ Department of Urology, IRCCS Istituto Nazionale dei Tumori, Milan, Italy
- ² Department of Surgery, Melanoma and Sarcoma, IRCCS Istituto Nazionale dei Tumori, Milan, Italy
- ³ Department of Pathology, IRCCS Istituto Nazionale dei Tumori, Milan, Italy

Corresponding author

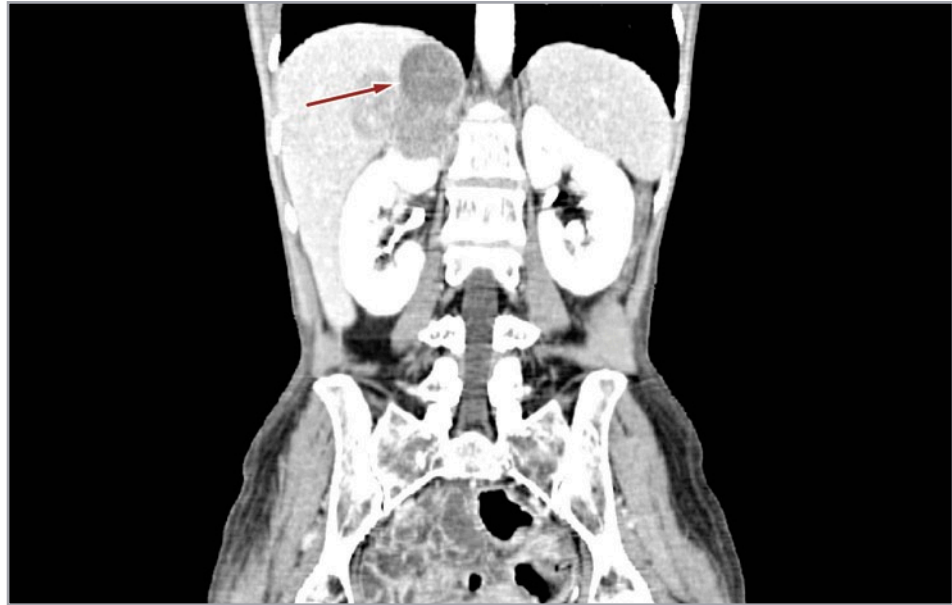
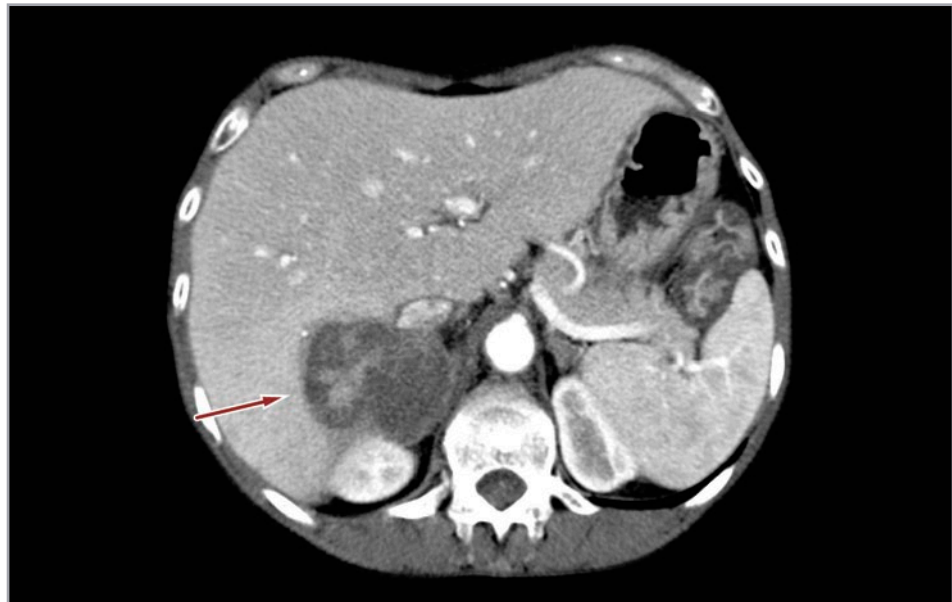Tullio Torelli
tullio.torelli@istitutotumori.mi.it

Disclosure

The authors declare they have no competing financial interests concerning the topics of this article

Figure 1.

Ultrasonography showing right adrenal mass (red arrow) infiltrating the upper pole of kidney and liver (one month before hospital admission)

**Figure 2.** *Abdominal computed tomography revealing the same adrenal mass (red arrow) in trasversal plan (one month before hospital admission)*

ultrasonography showed a nonspecific mass located around the upper pole of the right kidney and abdominal computed tomography revealed a right adrenal neoplasm measuring 45 × 29 mm in diameter and bulging out toward the liver (Figures 1 and 2).

Physical examination revealed a tender palpable right upper quadrant mass. Laboratory studies were significant for anemia (6.2 g/dl) and leukocytosis ($1.19 \times 10^3/\mu\text{l}$). Hormone panel including serum and urinary metanephrines, serum and urinary cortisol, plasma aldosterone, and serum adrenocorticotropic hormone was normal. Ten days after hospitalization, follow up chest-abdomen and pelvis CT scan re-

vealed enlargement of the adrenal mass from 45 × 29 mm to 65 × 45 mm. New bilateral lung nodules were also noted (Figures 3 and 4).

Therefore, fine-needle aspiration (FNA) was performed. Histological sections showed sheets of epithelioid cells in a fibrotic stroma and focal necrosis. Cells have eosinophilic cytoplasm, prominent nucleoli and frequent mitotic figures. These histologic features were consistent with malignant neoplasm. Further studies with pax8, cytokeratin 19, claudin, calretinin, synaptophysin, chromogranin A, glypican-3, human melanoma black 45 and MART-1, and cytokeratin (AE1/AE3) were performed. The

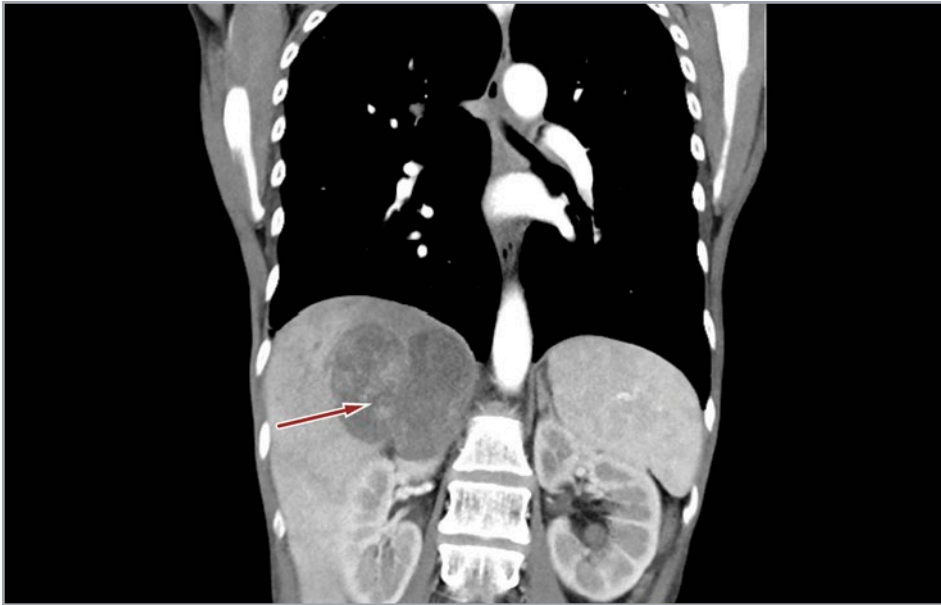


Figure 3. CT scan revealing growing adrenal mass (red arrow) with extensive infiltration of liver and upper pole of kidney (longitudinal plan, ten days after hospital admission)

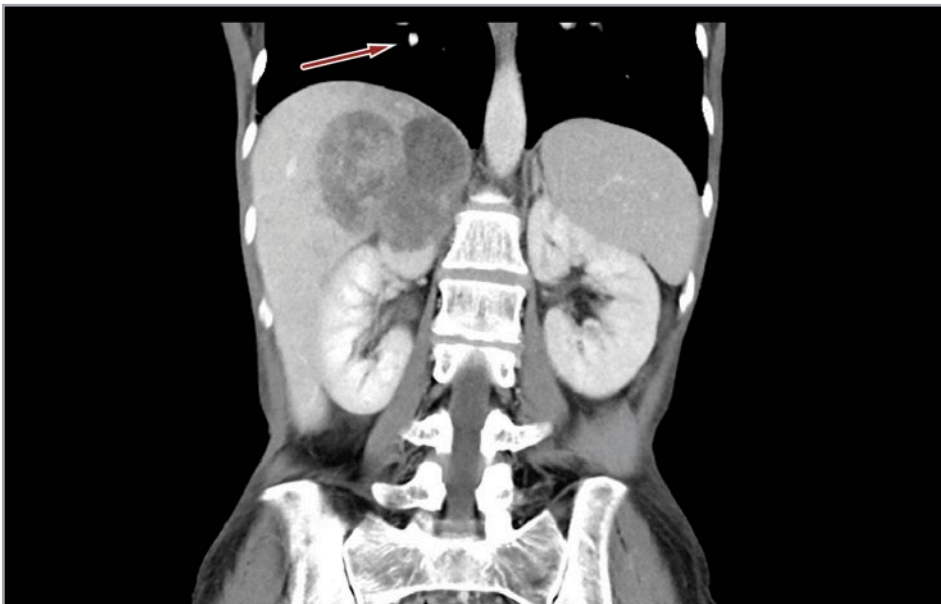


Figure 4. CT scan showing evidence of lung metastasis (red arrow) in right pulmonary lobe (ten days after hospital admission)

tumor cells were positive for cytokeratin and negative for all the remaining markers. A second panel of immunostains including CD31, cytokeratin, and ERG-1 was performed. Tumor cells were strongly positive for all (Figure 5). Hence, the diagnosis of

epithelioid angiosarcoma was made. Unfortunately, the patient died few days after the histological diagnosis.

DISCUSSION

Angiosarcomas are very rare malignant tumors, which derive from the vascular endothelium and can occur at any site in the body [2]. Epithelioid angiosarcoma (EA) of the adrenal gland has poor prognosis: 5-year overall survival ranges between 25% and 45% in primary tumors, while is shorter than 12 months in metastatic patients [3]. To our knowledge, just 37 case reports have

What should the clinician ask him/herself or the patient

- *Adrenal mass is rapidly growing?*
- *Are there general symptoms as asthenia, malaise, and mild fever?*
- *Hormonal activity is normal?*

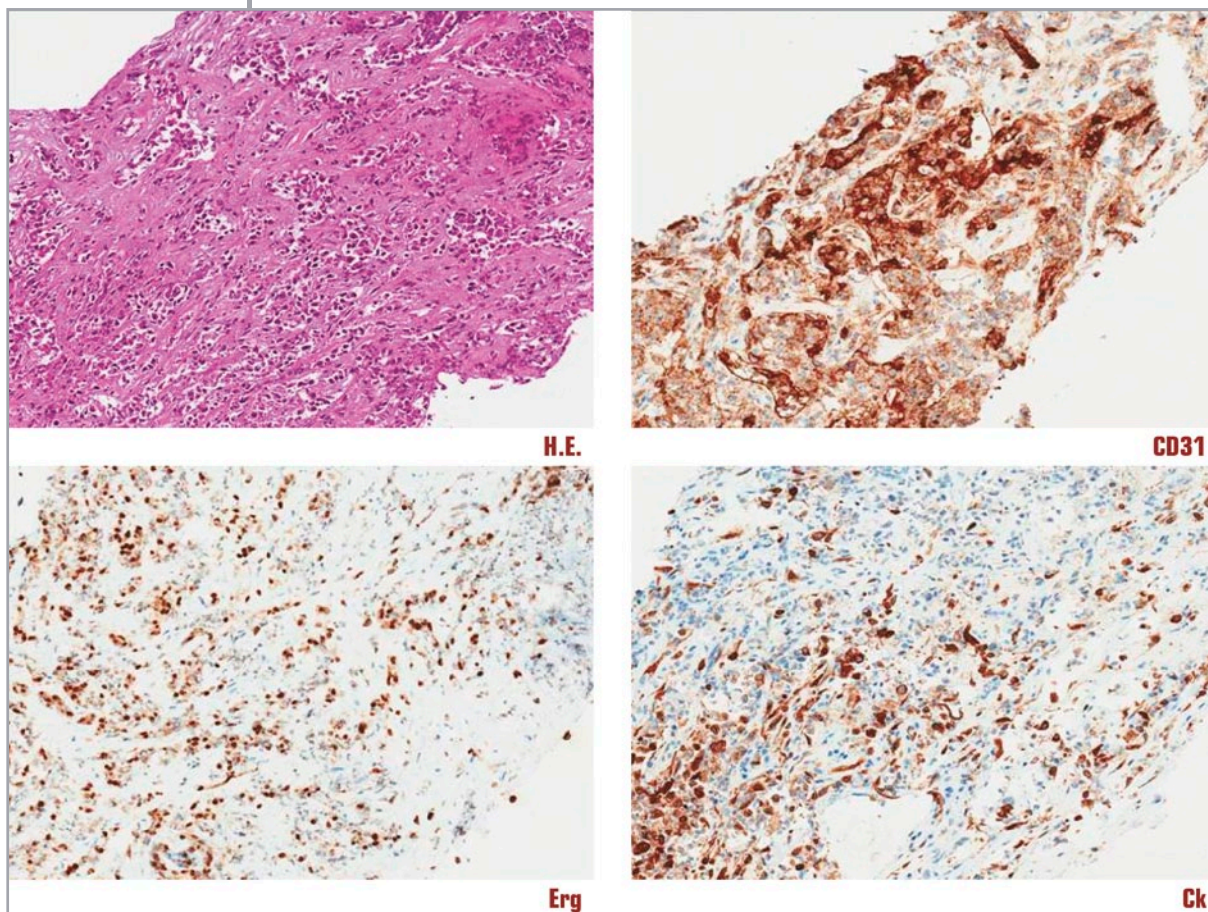


Figure 5. Hematoxylin-eosin (H.E.) staining and immunohistochemical studies

Ck = cytokeratin

been reported in literature. Nevertheless, among them, only 29 are available for full review in English, according to PubMed systemic research through MeSH terms (Table I) [4-33].

The etiology of EA remains unknown: apart from a case of exposure to arsenic [6]

and a case of exposure to vinyl chloride [29], the published case reports didn't succeed in identifying a clear correlation with the patients' exposure to carcinogens or with a significant incidence of other diseases, even though three patients had concomitant adrenal cortical adenoma [26,31,32] (Table I).

Case	Gender (age)	Clinical findings	CT scan findings	Side	Other disease	Therapy	Follow up	Ref.
1	M (54)	Abdominal pain	6 cm solid mass	L	None	Adrenalectomy + chemotherapy	Relapse after 7 months	4
2	F (54)	Fatigue, weight loss, paraneoplastic syndrome	6 cm soft tissue upper pole right kidney	R	None	Adrenalectomy	NED 6 months	5
3	M (58)	Abdominal pain	8 cm solid mass	R	Chronic arsenical intoxication	Adrenalectomy	Died after surgery	6
4	M (41)	Epigastric pain	10 cm rounded mass	R	Mesenteric fibromatosis	Adrenalectomy + radiotherapy	NA	7
5	M (67)	Abdominal pain	Inhomogeneous mass (13 cm)	L	None	Adrenalectomy	Died 2 months for lung mts	8
6	M (85)	Incidental findings (autopsy)	NA	R	None	None	None	9
7	F (60)	Abdominal pain	NA	R	None	Adrenalectomy	NED 13 years	9

Continues >

> Continued

Case	Gender (age)	Clinical findings	CT scan findings	Side	Other disease	Therapy	Follow up	Ref.
8	F (64)	Weight loss	10 cm suprarenal mass	L	None	Adrenalectomy	Died 12 months	9
9	F (60)	Left flank pain	Adrenal mass	L	None	Adrenalectomy	Died 2 months	9
10	M (82)	Incidental finding	NA	NA	NA	Adrenalectomy	Died 24 months (lung mts)	9
11	F (45)	Cushing's syndrome	Adrenal mass	R	None	Adrenalectomy	NED 11 years	9
12	M (56)	Fever, weakness	Adrenal mass	R	None	Adrenalectomy	Died 6 months (lung mts)	9
13	F (56)	Flank pain	Adrenal mass	L	None	Adrenalectomy + chemotherapy	NED 6 years	9
14	M (50)	Nausea, diarrhoea	5.5 solid mass, peritoneal mts	R	None	Adrenalectomy	Died 9 months (ileus)	10
15	M (50)	Fever, lumbar pain	6 cm solid mass bone, liver mts	R	None	Adrenalectomy + partial hepatectomy	Died after surgery	11
16	M (62)	Anorexia	Adrenal mass (10 cm)	L	None	Adrenalectomy	Died 7 weeks	12
17	M (63)	Incidental finding	3 cm solid mass	L	None	Laparoscopic adrenalectomy	NA	13
18	M (70)	Abdominal pain	8 cm solid mass	R	None	Adrenalectomy	Died 3 weeks	14
19	M (34)	Cushing's syndrome	4 cm irregular mass	L	Pituitary adenoma	Adrenalectomy	NED 2 years	15
20	F (70)	Abdominal pain	5 cm solid mass	R	Cistobiliary adenoma	Adrenalectomy	NED 18 months	16
21	M (61)	Abdominal pain	12 cm irregular mass	R	None	Adrenalectomy + nephrectomy	NED 3 years	17
22	M (71)	NA	NA	NA	NA	Adrenalectomy	NA	18
23	M (60)	Abdominal pain	11 cm solid and cystic mass	L	Colon polyposis	Adrenalectomy + radiotherapy + chemotherapy	Died 6 months (lung mts)	19
24	M (60)	NA	NA	NA	NA	Adrenalectomy + chemotherapy	NED 3 years	20
25	M (50)	Renal colic	7 cm mass at the upper pole kidney	L	None	Adrenalectomy + nephrectomy	NED 12 years	21
26	M (69)	Incidental	NA	NA	Prostate carcinoma	NA	NA	22
27	M (49)	Incidental	Large and cystic mass	R	Blunt abdominal trauma	Adrenalectomy	NED 1 year	23
28	M (55)	Abdominal mass, weight loss	10 cm solid mass	R	None	Adrenalectomy	Died 12 months (lung mts)	24
29	F (69)	Legs swellings	12.5 cm inhomogeneous mass	R	Chronic renal failure	Adrenalectomy + nephrectomy	NA	25
30	M (35)	Hypertension	6 cm inhomogeneous mass	R	Adrenocortical adenoma	Laparoscopic adrenalectomy	NED 2 years	26
31	M (61)	Fatigue, weight loss	Hypo-dense space-occupying lesion (PET)	R	Epicardial mts	Adrenalectomy	NA	27

Continues >

> Continued

Case	Gender (age)	Clinical findings	CT scan findings	Side	Other disease	Therapy	Follow up	Ref.
32	M (42)	Flank pain	Hypervascular solid mass (14 cm)	R	Cystic lesion of the adrenal gland	Adrenalectomy and nephrectomy	Died 3 months (liver mts)	28
33	M (68)	Left sided chest pain	Heterogeneous mass (7 cm)	L	Vinyl chloride exposition	Laparoscopic adrenalectomy	Died 7 months (bone mts)	29
34	M (55)	Abdominal mass, weight loss	14 cm solid mass	L	None	Adrenalectomy	NA	30
35	F (60)	Hypertension	5 cm solid mass	L	Adrenal cortical adenoma	Laparoscopic adrenalectomy	NED 9 months	31
36	M (63)	Weight loss	8 cm solid mass	R	Adrenal cortical adenoma	Adrenalectomy	NA	32
37	M (67)	Hypertension	16 cm heterogeneous mass	R	Left renal cell carcinoma	Adrenalectomy	NED 12 months	33

Table I. Case reports on epithelioid angiosarcomas retrieved in PubMed

L = left; mts = metastasis; NA = not available; NED = no evidence of disease; R = right

The disease occurs more frequently in males (M/F= 28/9), ranges from 34 to 85 years of age, with a mean peak at 57 years.

Patients can either be asymptomatic or suffer from weight loss, slight fever, anorexia, fatigue, weakness, and chronic pain in the upper abdominal quadrants, as in our patient. No increase in adrenal gland hormones production is noted in most of the reported cases, even though two patients had Cushing's syndrome [9,15] and in three patients the disease was discovered for the sudden onset of hypertension, despite none of them had increased plasmatic aldosterone or metanephrines [26,31,33].

Actually, CT scan is the most used radiological tool for diagnostic purpose, even if F¹⁸ FDG PET/CT may be useful too [27]. Although adrenal angiosarcoma does not have a distinct gross pattern, a review of the literature showed that it tends to have a round, solid, and heterogeneous aspect. Frequently, it is a cystic mass and can range in size from 3 cm to 16 cm (Table I). Clinicians and pathologists should include primary adrenal angiosarcoma in the differential diagnoses list for large adrenal gland mass [34].

One can speculate that the rich adrenal vasculature may create a favorable milieu for hemorrhagic and necrotic changes, while the high mitotic index may explain both the solid pattern and the huge volume of the tumor that is often found.

In this case, the differential diagnosis includes metastatic malignancy and other primary adrenal tumors. Epithelioid angiosarcomas can imitate carcinomas morphologically

and immune-phenotypically. Metastatic or primary melanoma can also show both epithelioid and spindled morphology. Among benign and malignant neoplasms that may simulate epithelioid angiosarcoma, there are adrenal adenoma undergoing massive hemorrhage and epithelioid hemangioendothelioma. Moreover, the diagnosis of angiosarcoma can be a challenge due to pathohistologic features mimicking intravascular papillary endothelial hyperplasia (IPEH – Masson's tumor). IPEH is a benign, reactive process that cannot be radiologically differentiated from other benign or malignant lesions [35].

Because of its rarity, in literature there is only one previous case of adrenal angiosarcoma diagnosed by fine-needle aspiration (FNA) [25]. In fact, owing to its epithelioid morphology, this tumor may be mistaken for other neoplasms. Sometimes, the difficult diagnosis may cause an insufficient surgical approach. If the tumor is confined to the adrenal gland, it is suggested to remove it, and also take the periadrenal fat tissue and pericaaval or periaortic tissue out in order to eradicate any site of potential local tumor microinfiltration. Involved organs, such as liver, spleen, pancreas, kidney, or bowel must be removed [16]. Too often, patients undergo surgery before a proper diagnosis is made and the high incidence of local relapses may sometimes be explained by inadequate approaches. Laparoscopy may be used carefully in district surgeries: among the studied case reports, it was used in four patients with a follow up no longer than one year [13,26,29,31].

Case	Gross finding	Ck	CD31	CD34	Factor VIII	Ki-67	Ref.
1	Solid and hemorrhagic mass	NA	NA	NA	NA	NA	4
2	Solid mass with a central hemorrhagic mass	Pos	NA	NA	Pos	NA	5
3	NA	NA	NA	NA	NA	NA	6
4	Hemorrhagic cyst	Pos	NA	NA	Pos	NA	7
5	Necrotic mass with nodules	NA	NA	NA	Pos	NA	8
6-13	Solid cystic mass	Pos	NA	Pos	Pos	NA	9
14	NA	NA	NA	NA	NA	NA	10
15	Hemorrhagic cystic lesion	Pos	Pos	Pos	Pos	NA	11
16	Hemorrhagic mass	Pos	Pos	Pos	Pos	NA	12
17	Hemorrhagic mass	Neg	NA	Pos	Pos	NA	13
18	Solid mass replacing the adrenal gland	Pos	Pos	Pos	Pos	NA	14
19	Multiple soft reddish nodules	Neg	Pos	Pos	Pos	30%	15
20	Hemorrhagic lesion	NA	Pos	NA	NA	NA	16
21	Hemorrhagic cystic mass	Pos	Pos	Neg	Neg	NA	17
22	NA	NA	NA	NA	NA	NA	18
23	Cystic mass with hemorrhagic areas	Neg	Pos	Pos	Pos	NA	19
24	Hemorrhagic cyst	Pos	Pos	Pos	NA	NA	20
25	Bilocular cyst containing thick material	Neg	Pos	NA	Pos	NA	21
26	NA	NA	NA	NA	NA	NA	22
27	Hemorrhagic mass	NA	NA	NA	NA	NA	23
28	Solid mass with hemorrhagic foci	Weak pos	Pos	Pos	Pos	NA	24
29	Biopsy: epithelioid cell	Pos	Pos	Pos	NA	NA	25
30	Lobulated mass with hemorrhagic foci	Pos	Pos	Pos	Pos	NA	26
31	NA	NA	NA	NA	NA	NA	27
32	Cystic changes with old hemorrhage	Pos	Pos	Neg	Neg	60%	28
33	Infiltrating hemorrhagic noduli	Focal pos	Pos	Neg	Pos	NA	29
34	NA	NA	NA	NA	NA	NA	30
35	Solid mass with hemorrhagic areas	Pos	Pos	Weak pos	Weak pos	NA	31
36	Areas of hemorrhage and necrosis	Pos	Pos	Neg	NA	NA	32
37	Hematoma	NA	Pos	Pos	Pos	NA	33

So far, diagnostic process is supported by histopathology and immunohistochemistry. Epithelioid angiosarcomas are morphological variants of angiosarcomas, in which polygonal endothelial cells with “epithelioid” appearance predominate and are often arranged in solid nests and sheets, mimicking carcinoma. Although irregular, anastomosing vascular channels are commonly identified within the lesion, supporting the diagnosis. Malignant cells stain positively for endothelial markers CD31, factor VIII, and Fli-1. CD34 is reported to be less sensitive even though it is present in about 40% of cases (Table II).

Most epithelioid angiosarcomas co-express cytokeratin and diagnostic errors may be promoted by immunohistochemical reactivity for this marker. In fact, cytokeratin reactivity may also occur in non-epithelial tumors like mesenchymal ones and the literature shows a lot of studies documenting the presence of cytokeratin in these tumors. Therefore, cytokeratin immunoreactivity may be considered as “aberrant expression” or “cross-reactivity” of this marker [36].

Surgery, combined with chemotherapy, represents the mainstay of treatment. Chemotherapy is preferably used in neoadjuvant setting to shrink the tumor and eventually

Table II.
Immunohistochemical and gross findings of reported cases

Ck = cytokeratin;
NA = not available

prevent local or distant spread. In these cases, histological diagnosis is mandatory, before therapy and FNA may play an important role, because this tumor has not specific clinical or radiological patterns. Most active agents are anthracycline, ifosfamide, gemcitabine, and taxanes.

In advanced or metastatic disease, cytotoxic chemotherapy based on the same active drugs is the treatment of choice. Even if the response rate of angiosarcoma to these treatments is higher than other tumors, in most cases their dose-limiting toxic effects (mostly cardiac and neurological) do not allow to use these therapies longer than 6 months [3]. Thus, new and non-toxic drugs are strongly needed. Among new anti-angiogenic therapies, activity of sorafenib, sunitinib, bevacizumab, and thalidomide has been recently described, obtaining response rates up to 15% [37,38]. Especially in palliative setting, where the goal is to increase survival and preserve the quality of life, the sequential use of taxanes and gemcitabine could be, probably in most cases, more advisable than their combination [39].

CONCLUSIONS

Epithelioid adrenal angiosarcoma is a very rare tumor and only 37 cases are reported in scientific literature. It is very aggressive and has poor long term prognosis. Such data show that early diagnosis is mandatory. Nevertheless, early diagnosis is rarely made since the tumor may be asymptomatic or present with aspecific symptoms, like slight fever, anorexia, fatigue or general pain or discomfort in the upper parts of the abdomen. Actually, endocrine tests are not indicative and the radiology workup may suggest just an indistinct malignancy.

Even if histomorphological and immunohistochemical studies are time-consuming, they are an essential part of the definitive diagnosis and FNA may be an helpful tool to obtain a preoperative and definitive diagnosis.

Unfortunately, sometimes diagnosis is made when disease is advanced, with no therapeutic options, as happened in this case.

Key points

- *Epithelioid adrenal angiosarcoma is a very rare and aggressive tumor*
- *Even if early diagnosis is mandatory, endocrine tests are not indicative and radiology workup shows an indistinct malignancy*
- *Histological diagnosis, supported by histopathology and immunohistochemistry, is essential for the best management performed by neoadjuvant chemotherapy and district surgery*
- *It may be important for clinicians to obtain a preoperative diagnosis by FNA*

REFERENCES

1. Hart J, Mandavilli S. Epithelioid angiosarcoma. A brief diagnostic review and differential diagnosis. *Arch Pathol Lab Med* 2011; 135: 268-72
2. Fayette J, Martin E, Piperno-Neumann S, et al. Angiosarcoma, a heterogeneous group of sarcomas with specific behavior depending on primary site: a retrospective study of 161 cases. *Ann Oncol* 2007; 18: 2030-6; <https://doi.org/10.1093/annonc/mdm381>
3. Young RJ, Brown NJ, Reed MW, et al. Angiosarcoma. *Lancet Oncol* 2010; 11: 983-91; [https://doi.org/10.1016/S1470-2045\(10\)70023-1](https://doi.org/10.1016/S1470-2045(10)70023-1)
4. Kareti LR, Katlein S, Siew S, et al. Angiosarcoma of the adrenal gland. *Arch Pathol Lab Med* 1988; 112: 1163-5
5. Bosco PJ, Silverman ML, Zinman LM. Primary angiosarcoma of adrenal gland presenting as paraneoplastic syndrome: case report. *J Urol* 1991; 146: 1101-3
6. Livaditou A, Alexiou G, Floros D, et al. Epithelioid angiosarcoma of the adrenal gland associated with chronic arsenic intoxication? *Pathol Res Pract* 1991; 187: 284-9; [https://doi.org/10.1016/S0344-0338\(11\)80785-5](https://doi.org/10.1016/S0344-0338(11)80785-5)
7. Ben-Izhac O, Auslander L, Rabinson S, et al. Epithelioid angiosarcoma of the adrenal gland with cytokeratin expression. Report of a case with accompanying mesenteric fibromatosis.

- Cancer* 1992; 69: 1808-12; [https://doi.org/10.1002/1097-0142\(19920401\)69:7<1808::AID-CNCR2820690724>3.0.CO;2-E](https://doi.org/10.1002/1097-0142(19920401)69:7<1808::AID-CNCR2820690724>3.0.CO;2-E)
8. Fiordelise S, Zangrandi A, Tronci A, et al. Angiosarcoma of the adrenal gland. *Arch Ital Urol Nefrol Androl* 1992; 64: 341-3
 9. Wenig BM, Abbondanzo SL, Heffess CS. Epithelioid angiosarcoma of the adrenal glands. A clinicopathologic study of nine cases with a discussion of the implications of finding "epithelial-specific" markers. *Am J Surg Pathol* 1994; 18: 62-73; <https://doi.org/10.1097/00000478-199401000-00006>
 10. Schwenk W, Sarbia M, Hass R, et al. Primary hemangiosarcoma as a rare form of an incidentally discovered mass of the adrenal glands. *Dtsch Med Wochenschr* 1994; 119: 217-21
 11. Jochum W, Schroder S, Risti B, et al. Cytokeratin-positive angiosarcoma of the adrenal gland. *Pathologe* 1994; 15: 181-6; <https://doi.org/10.1007/s002920050043>
 12. Sasaki R, Tachiki Y, Tsukada T, et al. A case of adrenal angiosarcoma. *Nihon Hinyokika Gakkai Zasshi* 1995; 86: 1064-7; <https://doi.org/10.5980/jpnjurol1989.86.1064>
 13. Croitoru AG, Klausner AP, McWilliams G, et al. Primary epithelioid angiosarcoma of the adrenal gland. *Ann Diagn Pathol* 2001; 5: 300-3; <https://doi.org/10.1053/adpa.2001.27917>
 14. Kruger S, Kujath P, Johannisson R, et al. Primary epithelioid angiosarcoma of the adrenal gland. Case report and review of the literature. *Tumori* 2001; 87: 262-5
 15. Invitti C, Pecori Giraldi F, Cavagnini F, et al. Unusual association of adrenal angiosarcoma and Cushing's disease. *Horm Res* 2001; 56: 124-9
 16. Pasqual E, Bertolissi F, Grimaldi F, et al. Adrenal angiosarcoma: report of a case. *Surg Today* 2002; 32: 563-5; <https://doi.org/10.1007/s005950200099>
 17. Rodriguez-Pinilla SM, Benito-Belinchés A, Ballestin C, et al. Angiosarcoma of adrenal gland. Report of a case and review of the literature. *Rev Esp Patol* 2002; 35: 227-32
 18. Tousi-Sadr HR, Lam GW. Angiosarcoma of the adrenal gland. *Ugeskr Laeger* 2002; 164: 911-2
 19. Artal EM, Gomez-Aracil V, Sole-Poblet JM, et al. Angiosarcoma epiteloide de suprarenal. A proposito de un caso. *Arch Esp Urol* 2002; 55: 261-4
 20. Sidoni A, Magro G, Cavaliere A, et al. Primary adrenal angiosarcoma. *Pathologica* 2003; 95: 60-3
 21. Al-Meshan MK, Katchy KC. An unusual angiosarcoma. *Med Princ Pract* 2004; 13: 295-7; <https://doi.org/10.1159/000079532>
 22. Galmiche L, Morel HP, Moreau A, et al. Angiosarcome primitif suralieu. *Annales de Pathologie* 2004; 24: 371-3; [https://doi.org/10.1016/S0242-6498\(04\)93987-9](https://doi.org/10.1016/S0242-6498(04)93987-9)
 23. Gambino G, Mannone T, Rizzo A, et al. Adrenal epithelioid angiosarcoma: a case report. *Chir Ital* 2008; 60: 463-7
 24. Stavridis S, Mickovski A, Filipovski V, et al. Epithelioid angiosarcoma of the adrenal gland. Report of a case and review of the literature. *Maced J Med Sci* 2010; 3: 388-94
 25. Schreiner AM, Hoda RS. Primary adrenal epithelioid angiosarcoma showing rhabdoid morphology in air-dried smears. *Diagnostic Cytopathology* 2011; 40: E162-E164; <https://doi.org/10.1002/dc.21690>
 26. Lepoutre Lussey C, Rousseau A, Al Ghuzlan A, et al. Primary adrenal angiosarcoma and functioning adrenocortical adenoma: an exceptional combined tumor. *Eur J Endocr* 2012; 166: 131-5; <https://doi.org/10.1530/EJE-11-0791>
 27. Derlin TD, Claudiz TS, Habermann CR. Adrenal epithelioid metastatic to epicardium. Diagnosis by F18-FDG PET/CT. *Clin Nucl Med* 2012; 37: 914-5; <https://doi.org/10.1097/RLU.0b013e318262af6b>
 28. Sung JY, Ahn S, Kim SJ, et al. Angiosarcoma arising within a long standing cystic lesion of the adrenal gland. A case report. *J Clin Oncol* 2013; 31: e132-e136; <https://doi.org/10.1200/JCO.2012.44.0800>
 29. Crisculo M, Valerio J, Gianicolo ME, et al. A vinyl chloride-exposed worker with an adrenal gland angiosarcoma: a case report. *Industrial Health* 2014; 52: 66-70; <https://doi.org/10.2486/indhealth.2013-0044>
 30. Kedzierski L, Kawecka AH, Holecki M, et al. Angiosarcoma of the adrenal gland. *Pol Arch Med Wn* 2013; 123: 502-3
 31. Hendry S, Forrest C. Epithelioid angiosarcoma arising in a adrenal cortical adenoma: a case report and review of the literature. *Int Jour Surg Pathol* 2014; 22: 744-8; <https://doi.org/10.1177/1066896914532541>
 32. Hayashi T, Gucer H, Mete O. A mimic of sarcomatoid adrenal cortical carcinoma: epithelioid angiosarcoma occurring in adrenal cortical adenoma. *Endocr Pathol* 2014; 25: 404-9; <https://doi.org/10.1007/s12022-014-9330-y>

33. Gusenbauer K, Ruzhynsky V, Kak I, et al. Angiosarcoma of the adrenal gland with concurrent contralateral advanced renal cell carcinoma: a diagnostic and management dilemma. *Can Urol Assoc J* 2015; 9: E302-E305
34. Yip L, Tublin ME, Falcone JA, et al. The adrenal mass: correlation of histopathology with imaging. *Ann Surg Onc* 2010; 17: 846-52; <https://doi.org/10.1245/s10434-009-0829-2>
35. Akdur NC, Donmez M, Gozel S, et al. Intravascular papillary endothelial hyperplasia: histomorphological and immunohistochemical features. *Diag Pathol* 2013; 8: 167; <https://doi.org/10.1186/1746-1596-8-167>
36. Swanson PE. Heffalumps, jagulars and cheshire cats: a commentary on cytokeratins and soft tissue sarcomas. *Am J Clin Pathol* 1991, 95(suppl.1): 2-7
37. Ray-Coquard I, Italiano A, Bompas E, et al. Sorafenib for patients with advanced angiosarcoma: a phase II Trial from the French Sarcoma Group (GSF/GETO). *Oncologist* 2012; 17: 260-6; <https://doi.org/10.1634/theoncologist.2011-0237>
38. Van Der Graaf WTA, Genderblom H. New systemic therapy options for advanced sarcoma. *Curr Treat Options Oncol* 2012; 13: 306-17; <https://doi.org/10.1007/s11864-012-0196-2>
39. Stacchiotti S, Palassini E, Sanfilippo R, et al. Gemcitabine in advanced angiosarcoma: a retrospective case series analysis from the Italian Rare Cancer Network. *Ann Oncol* 2012; 23: 501-8; <https://doi.org/10.1093/annonc/mdr066>